

Normal Skin

**Squamous Cell
Carcinoma**

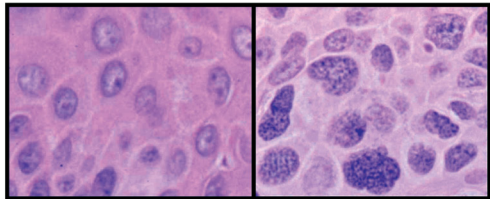


Figure 3. Chromatin Structural Changes in Cancer Cells

These two photomicrographs were taken from a patient with a squamous cell carcinoma of the skin. The left panel shows normal epidermal cells within one millimeter of the contiguous tumor, shown at the same magnification on the right. The chromatin, which stains purple due to its affinity to hematoxylin, appears much more coarse and granular in the cancer cells than in normal epidermis. Such changes in the staining characteristics of chromatin are used by pathologists as diagnostic criteria for cancer.